

Lyme endocarditis

N. Hidri¹, O. Barraud¹, S. de Martino², F. Garnier¹,
F. Paraf^{3,4}, C. Martin¹, S. Sekkal⁵, M. Laskar⁵, B. Jaulhac²
and M.-C. Ploy¹

1) CHU Limoges, Laboratoire de Bactériologie-Virologie-Hygiène, Limoges, 2) Centre National de Référence des *Borrelia*, Laboratoire de Bactériologie des Hôpitaux Universitaires de Strasbourg, Strasbourg, 3) CHU Limoges, Service d'Anatomie Pathologique, Limoges, 4) Univ Limoges, EA 3842 Faculté de Médecine, Limoges, and 5) CHU Limoges, Service de Chirurgie Thoracique et Cardio-Vasculaire et Angiologie, Limoges, France

Abstract

Lyme borreliosis is a common tick-borne disease with a wide variety of clinical manifestations. Cardiac involvement has been reported during both the acute phase (atrioventricular block, pericarditis) and the chronic stage (dilated cardiomyopathy), but is rare (<5%). Here we describe the first case of *Borrelia afzelii* Lyme endocarditis, in a 61-year-old man living in an endemic area of France. The diagnosis was confirmed by detection of *B. afzelii* DNA in the mitral valve by specific real-time PCR. He was treated empirically with amoxicillin for 6 weeks and remains well 12 months later.

Keywords: *B. afzelii*, *Borrelia*, borreliosis, endocarditis, lyme

Original Submission: 1 July 2012; **Revised Submission:** 22 August 2012; **Accepted:** 24 August 2012

Editor: D. Raoult

Clin Microbiol Infect

Corresponding author: Marie-Cécile Ploy, Laboratoire de Bactériologie-Virologie-Hygiène, CHU Limoges, 2 Avenue Martin Luther King, 87042 Limoges cedex, France
E-mail: marie-cecile.ploy@unilim.fr

Lyme borreliosis (or Lyme disease) is the most commonly reported tick-borne disease in the northern hemisphere, notably in Europe and North America. The different species of the *Borrelia burgdorferi* sensu lato group are transmitted by infected ticks of the genus *Ixodes*. Whereas only one bacterial species, *B. burgdorferi* sensu stricto, is currently recognized as pathogenic in North America, several pathogenic species are present in Europe (mainly *B. burgdorferi* sensu

stricto, *B. afzelii* and *B. garinii*), where they cause a wider variety of clinical manifestations [1]. Typically, following initial erythema migrans at the tick bite site, these bacteria can spread from the skin to other tissues and organs, causing more severe manifestations such as arthritis and cutaneous and neurological disorders [2]. Cardiac Lyme borreliosis is rare, representing only 0.3–4% of cases in Europe, and is generally associated with acute-onset atrioventricular (I–III) conduction disorders, arrhythmias and, in some cases, myocarditis or pericarditis [3–8]. Here we describe a documented case of Lyme endocarditis.

A 61-year-old man was admitted in March 2011 to Limoges University Hospital, France, for mitral valve replacement. He was an ex-smoker, had a history of paroxysmic auricular fibrillation, and had mitral insufficiency due to mitral valve prolapse. Initial investigations showed auricular fibrillation and dyspnoea, mitral regurgitation with rope rupture, an ejection fraction of 45%, and a dilated left atrium on cardiac ultrasound. During surgery the macroscopic aspect of the mitral valve suggested endocarditis, with prolapse of the posterior valve and a 5-mm² perforation of the anterior valve. All blood cultures and serologies commonly performed in the case of endocarditis (*Bartonella henselae*, *Bartonella quintana*, *Mycoplasma pneumoniae*, *Legionella pneumophila*, *Chlamydia pneumoniae* and *Coxiella burnetii*) were all negative. He was treated empirically with intravenous amoxicillin and gentamicin for 2 weeks, followed by oral amoxicillin for 4 weeks. Microscopic analysis of the mitral valve showed endocarditis with foamy macrophages suggestive of intracellular microorganisms (Photo 1). Gram, PAS and Gimenez stains were negative. Whartin-Starry stain showed only

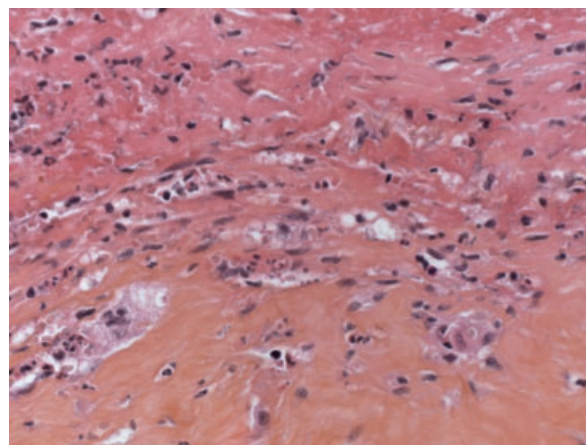


PHOTO 1 Microscopic view of the mitral valve showing surface fibrin deposit, and sparse inflammatory infiltrate consisting of foamy macrophages, neutrophils and eosinophils (hematein eosin saffron $\times 400$).

scarce curved rods, which had a morphology that was not specific to Spirochaetes. Universal PCR targeting 16S RNA-encoding DNA was applied to a valve fragment and the amplification product was sequenced, identifying the genus *Borrelia*. Two valve fragments were sent to the French *Borrelia* National Reference Center for confirmation. Both were positive by specific real-time PCR using a Taqman® probe targeting a conserved region of the flagellin (*Fla*) gene of the *Borrelia burgdorferi sensu lato* (Bbsl) complex [9]. Further real-time DNA amplification using hybridization probes targeting species-specific regions of the *fla* gene identified *B. afzelii*. The Anti-*Borrelia* Plus VlsE ELISA IgG assay was positive and the Anti-*Borrelia* ELISA IgM assay was negative (both tests from Euroimmun AG, Luebeck, Germany). Western blot (*Borrelia afzelii* + VlsE Eco Blot IgG Western Blot; Virotech, Rüsselsheim, Germany) confirmed the presence of several antibodies targeting the VlsE, p83, p58, p39, p31 and p21 proteins. Only atrial fibrillation persisted after antibiotic treatment, with no mitral regurgitation. As the patient was well, and given the lack of specific therapeutic guidelines for Lyme endocarditis, antibiotic treatment was not prolonged or changed. The patient did not recall a tick bite, a previous episode of *erythema migrans*, or secondary manifestations such as meningoradiculitis.

To our knowledge this is the first documented case of *B. afzelii* Lyme endocarditis. In Europe, *B. afzelii* is commonly associated with neurological and late cutaneous manifestations, and less frequently with arthritis. Only one previous publication mentions detection of the weakly pathogenic species *B. bissettii* in a patient's cardiac valve tissue, in the Czech Republic, without mentioning Lyme endocarditis diagnosis [10]. Borreliosis is endemic in our patient's home region (Limousin), with an estimated seroprevalence of 42 cases per 100 000 inhabitants [11]. *B. burgdorferi* seropositivity is very common in endemic areas, and cannot serve as a definitive diagnostic criterion, as underlined by Kaell *et al.* [12] and Stanek *et al.* [2]. The exceptional case of Lyme endocarditis described here emphasizes the need to perform universal PCR on heart valve samples in the case of endocarditis of unknown origin, and to bear in mind the possibility of borrelial aetiology in endemic areas.

Acknowledgments

The authors gratefully thank Dr Daniel Lascaux (general practitioner) for his contribution to the work.

Authors' Contributions

NH collected all results; OB wrote the report; SDM, FG and CM carried out microbiological analyses; SS and ML managed the patient; FP carried out microscopic analyses; BJ and MCP reviewed the report.

Conflict of Interest

Written consent to publish was obtained. The authors declare no conflicts of interest.

Transparency Declaration

The authors declare no conflicts of interest.

References

1. Stanek G, Wormser GP, Gray J, Strle F. Lyme borreliosis. *Lancet* 2011; 379: 461–473.
2. Stanek G, Fingerle V, Hunfeld KP *et al.* Lyme borreliosis: clinical case definitions for diagnosis and management in Europe. *Clin Microbiol Infect* 2011; 17: 69–79.
3. Gildein HP, Gunther S, Mocellin R. Complete heart block in a 9 year old girl caused by borreliosis. *Br Heart J* 1993; 70: 88–90.
4. Tavora F, Burke A, Li L, Franks TJ, Virmani R. Postmortem confirmation of lyme carditis with polymerase chain reaction. *Cardiovasc Pathol* 2008; 17: 103–107.
5. Palecek T, Kuchynka P, Hulinska D *et al.* Presence of *Borrelia burgdorferi* in endomyocardial biopsies in patients with new-onset unexplained dilated cardiomyopathy. *Med Microbiol Immunol* 2010; 199: 139–143.
6. Lelovas P, Dontas I, Bassiakou E, Xanthos T. Cardiac implications of lyme disease, diagnosis and therapeutic approach. *Int J Cardiol* 2008; 129: 15–21.
7. Lardieri G, Salvi A, Camerini F, Cinco M, Trevisan G. Isolation of *Borrelia burgdorferi* from myocardium. *Lancet* 1993; 342: 490.
8. Strle F, Stanek G. Clinical manifestations and diagnosis of Lyme borreliosis. *Curr Probl Dermatol* 2009; 37: 51–110.
9. Woods A, Soulas-Sprauel P, Jaulhac B *et al.* Myd88 negatively controls hypergammaglobulinemia with autoantibody production during bacterial infection. *Infect Immun* 2008; 76: 1657–1667.
10. Rudenko N, Golovchenko M, Mokracek A *et al.* Detection of *Borrelia bissettii* in cardiac valve tissue of a patient with endocarditis and aortic valve stenosis in the Czech Republic. *J Clin Microbiol* 2008; 46: 3540–3543.
11. Letrilliart L, Ragon B, Hanslik T, Flahault A. Lyme disease in France: a primary care-based prospective study. *Epidemiol Infect* 2005; 133: 935–942.
12. Kaell AT, Redecha PR, Elkon KB *et al.* Occurrence of antibodies to *Borrelia burgdorferi* in patients with nonspirochetal subacute bacterial endocarditis. *Ann Intern Med* 1993; 119: 1079–1083.